

## A Case of the 10 days

### Case 2

A fifty three-year-old female suffering from neck pain with fever was diagnosed cervical disk hernia with pharyngitis and given oral pain-free analgetics and antibiotics from a local clinic seven days ago. Because the neck pain and fever of around 38 centigrade did not improve, she came to our hospital for the further investigation. Laboratory test revealed elevation of white blood cells of 27500/mm<sup>3</sup>(4-8000) and CRP of 31.9 mg/dl(<0.3) and neutrophils of 89.2 % (40-71).

Fig 1  
An axial image  
of enhanced CT

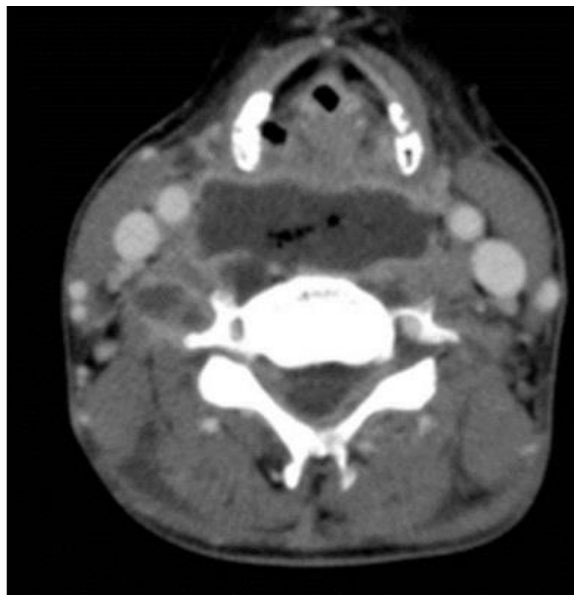


Fig.2  
A coronal image  
of enhanced CT

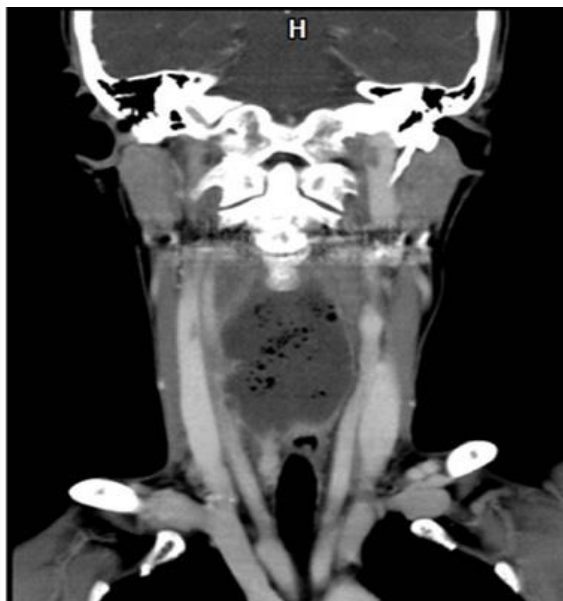
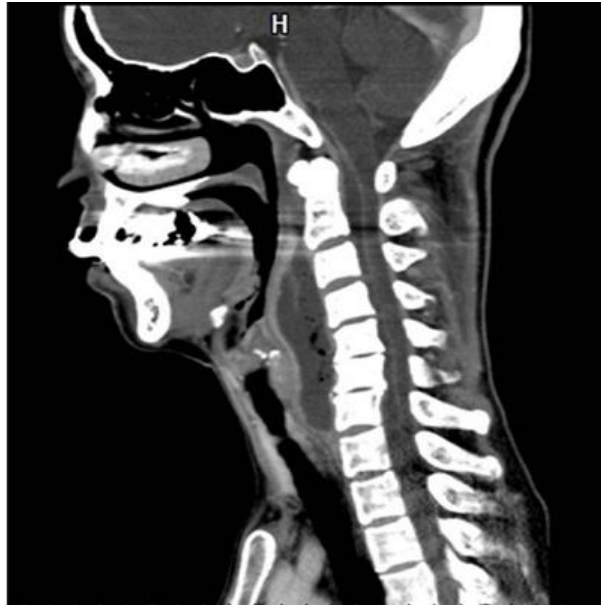
Fig. 3  
A sagittal image  
of enhanced CT



What is the diagnosis ?

---

1. Pharyngeal cancer
2. Esophageal cancer
3. Malignant lymphoma
4. Peri-tonsillar abscess
5. Retropharyngeal abscess

answer