

A Case of the 10 days

Case 233

An eighty three-year-old female presented in our hospital for nausea, fever, abdominal pain and bloody diarrhea. She experienced bloody stool several times for the past ten years. Medical palpation indicated tenderness on her whole abdomen. Laboratory test revealed white blood cells 12760/mm³ neutrophils 96%, CRP 15.04 mg/dL and platelets 155000/mm³. She agreed to take non-enhanced CT (Figs 1 to 3).

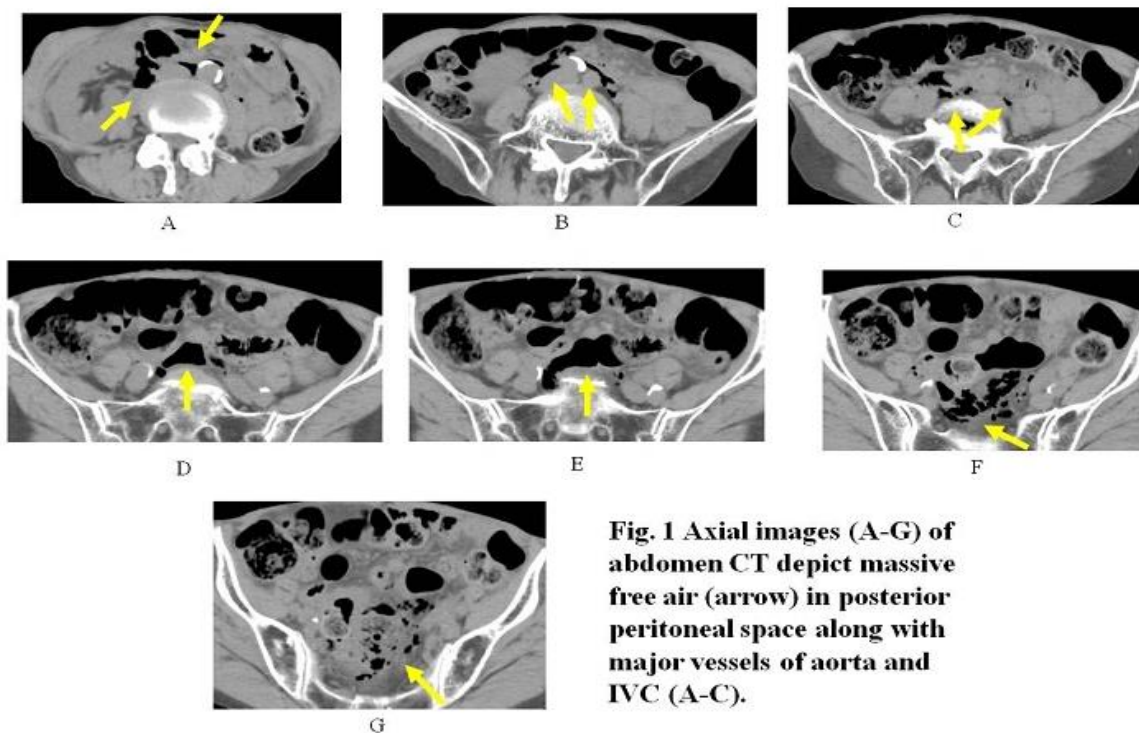


Fig. 1 Axial images (A-G) of abdomen CT depict massive free air (arrow) in posterior peritoneal space along with major vessels of aorta and IVC (A-C).

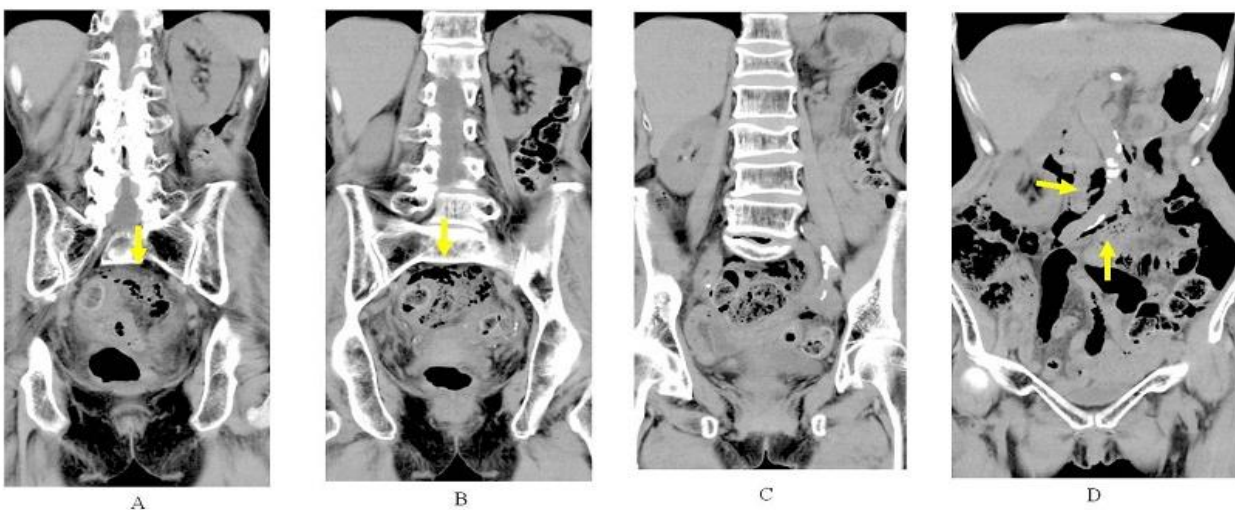
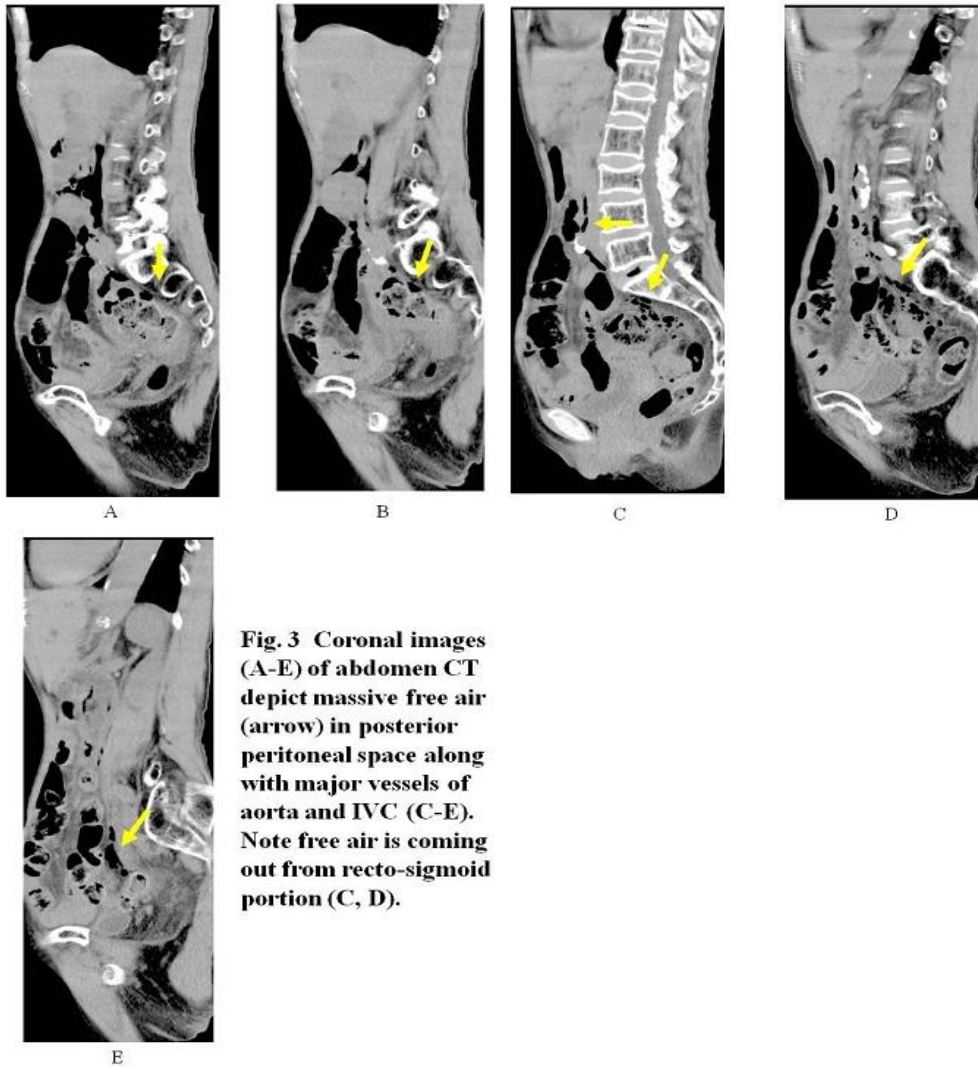


Fig. 2 Coronal images (A-D) of abdomen CT depict massive free air (arrow) in posterior peritoneal space along with major vessels of aorta and IVC (D).



What is your imaging diagnosis ?

1. Pneumatosis cystoides intestinalis
2. Diverticulitis of the sigmoid colon
3. Perforation of sigmoid colon
4. Ulcerative colitis
5. Rectal cancer

answer

2021.6.2