

## A Case of the 10 days

### Case 384

An eighty-eight-year-old male presented in our hospital for diarrhea several times a day for a week. He took abdomen CT for further investigation. (Figs.1, 2).

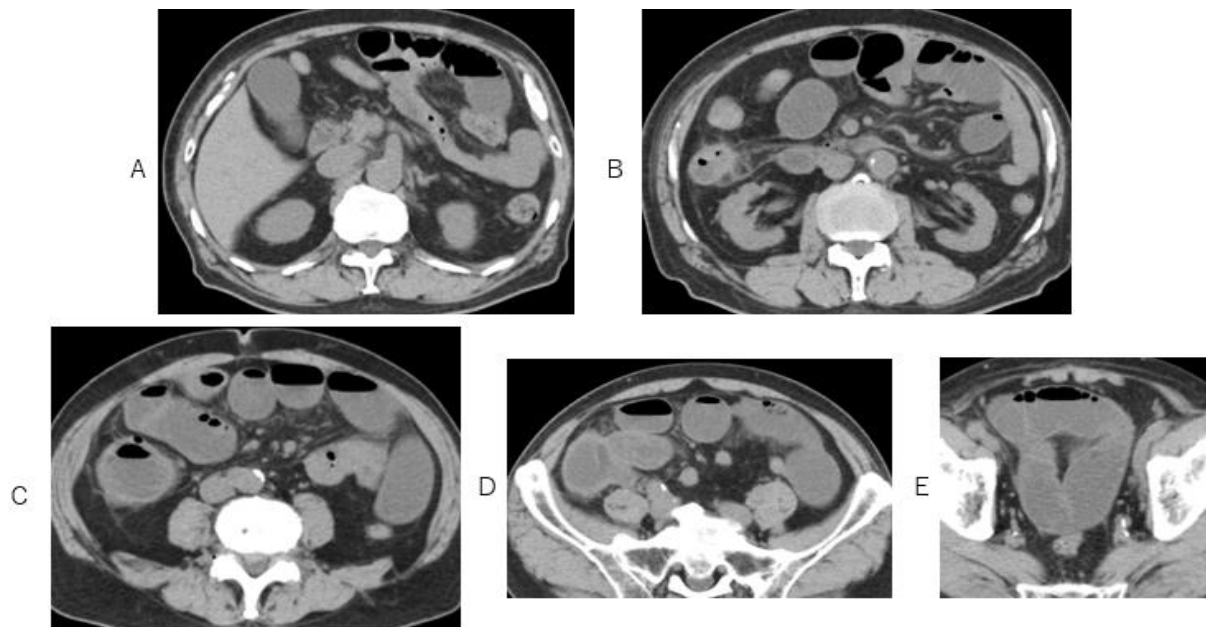


Fig.1 Axial CT images depict dilated small intestine with fluids and gas, diameters of small intestine are 3cm or greater.

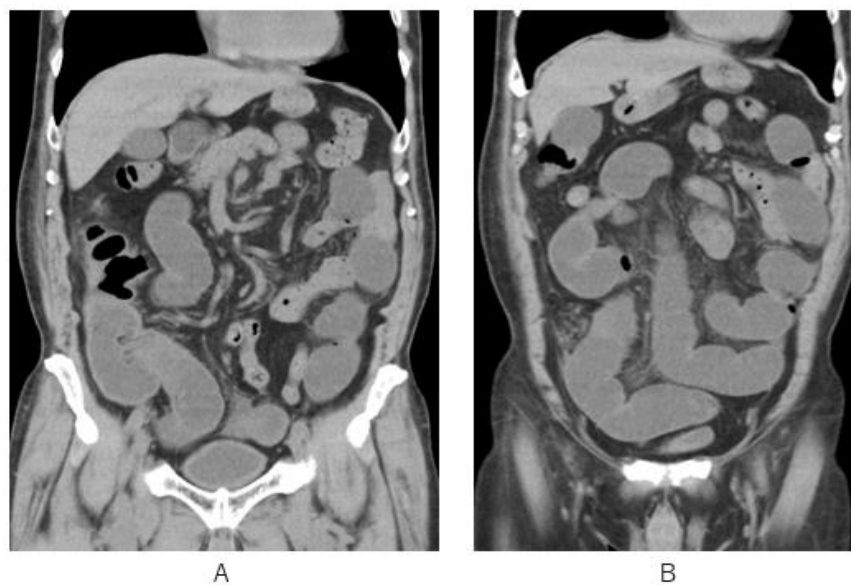


Fig.2 Coronal CT images depict dilated lower small bowel whose maximum diameter is 3cm or greater (A, B). Note the ileum end and cecum dilated with fluids and gas (A).

What is the imaging diagnosis?

---

1. Infectious bowel disease
2. Drug induced bowel disease
3. Adhesive ileus
4. Strangulation ileus

answer

2025.4.25