

A Case of the Week

Case 406

A seventy-six-year-old female presented in our hospital for hem stool several times. She underwent hemicolectomy for repeated bleeding from diverticula. She took chest to abdomen CT for investigation twice on November 5th, 2021 and on May 29th, 2025 (Figs. 1, 2).

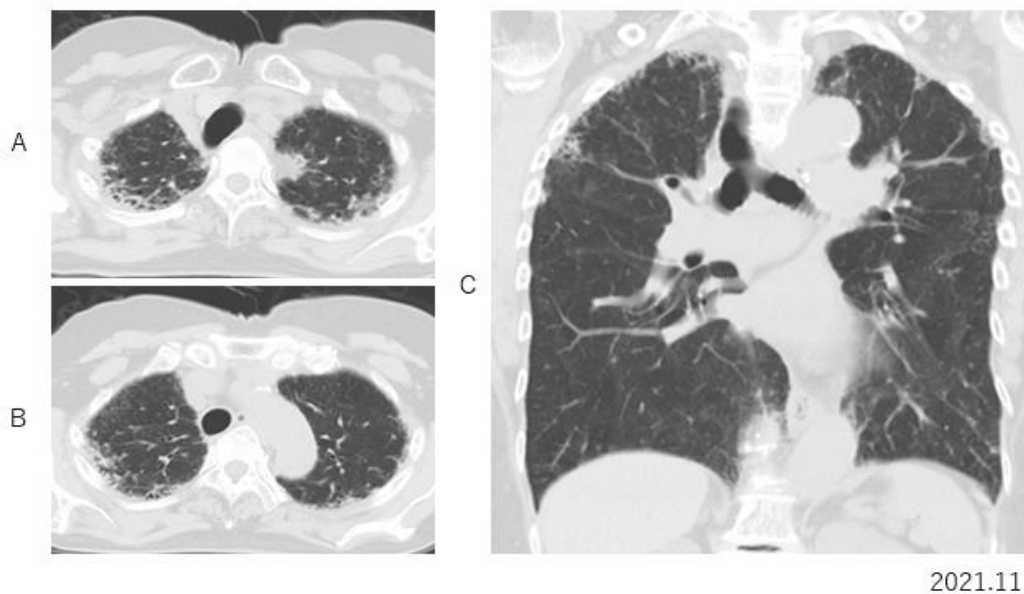


Fig.1 In bilateral apex, mild reticular fibrous pleural thickening is depicted on axial (A, B) and coronal CT.

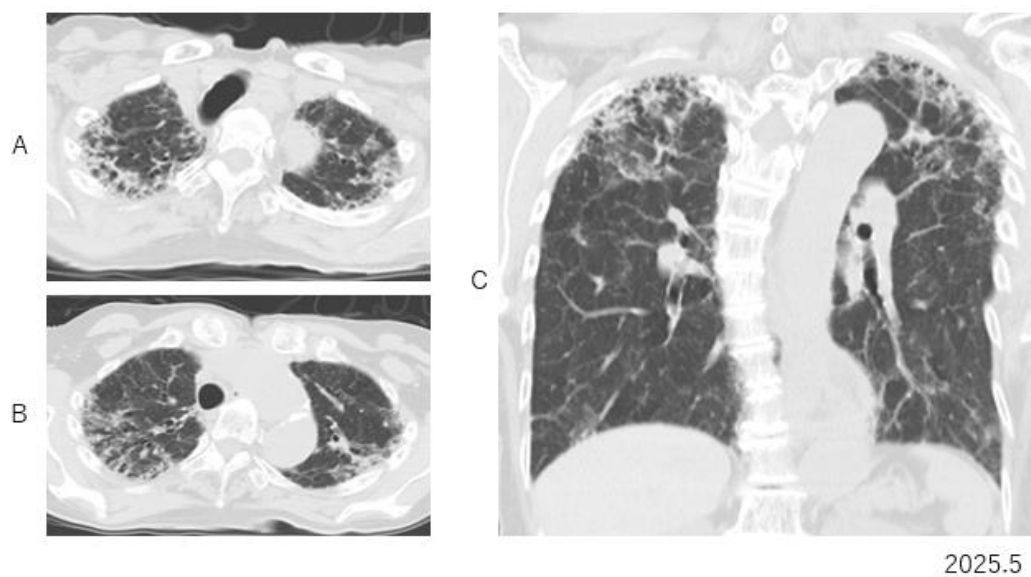


Fig.2 Four tears later, increasing in the degree of apical reticular pleural thickening is depicted on axial (A, B) and coronal CT (C).

What is an imaging diagnosis?

1. **Silicosis**
2. **Pulmonary tuberculosis**
3. **Kansasii disease (non-tuberculosis mycobacterium)**
4. **Pleuro-parenchymal fibro-elastosis**
5. **Pulmonary emphysema**

answer

2025.10.3