

A Case of the Week

Case 420

A fifty-year-old male presented as off-hour consultation with general fatigue, cough, white sputum. He had past-illness history of suffering from rheumatoid arthritis. He took chest CT for further investigation (Figs 1-3).

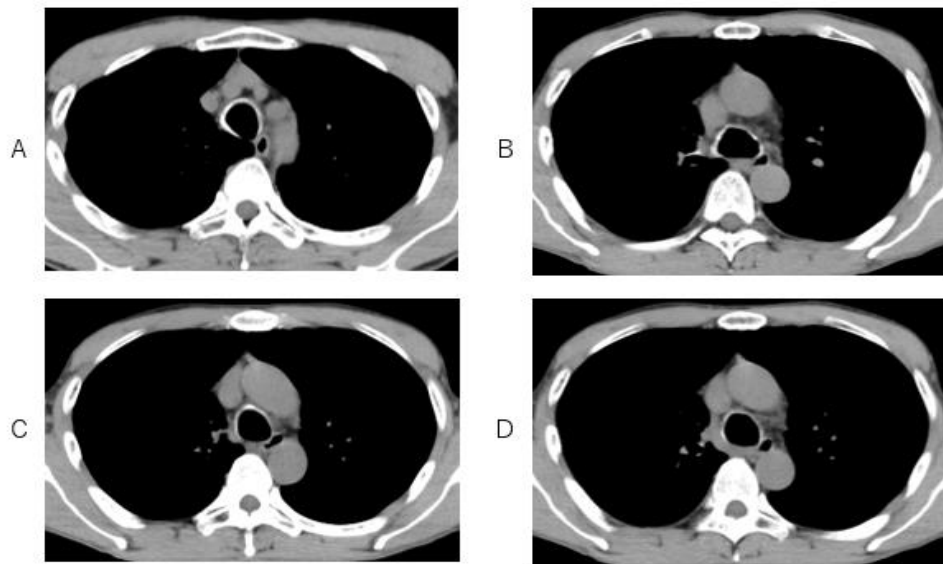


Fig.1 Bronchial cartilages are incorporated at the anterior and lateral bronchial wall but not at posterior bronchial wall on chest CT with mediastinal level.

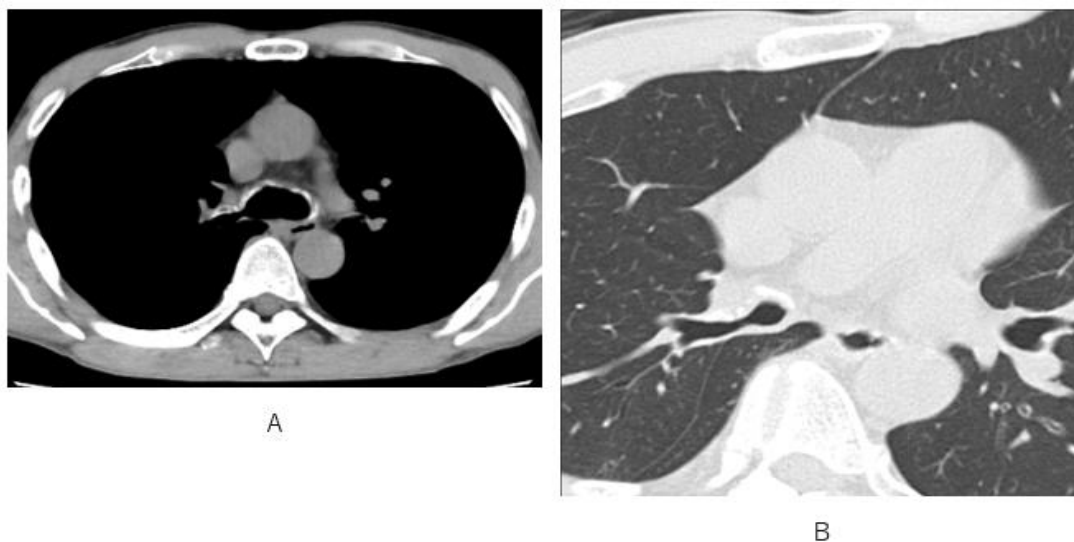

Fig.2 Stenotic right main bronchus with calcified cartilage at anterior bronchus wall is depicted on CT with mediastinal level (A) and pulmonary level (B).

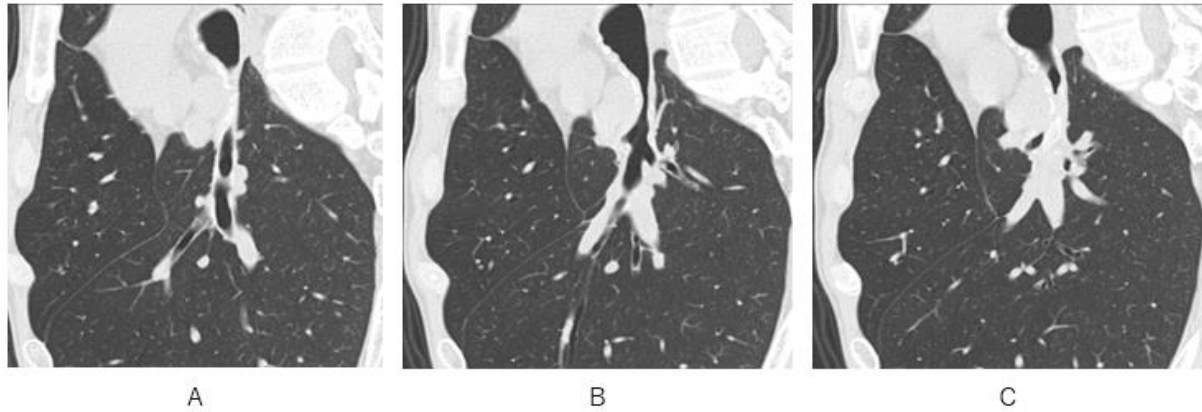


Fig.3 Stenosis of right main bronchus is depicted clearly on oblique sagittal CT.

What is an imaging diagnosis for stenotic right main bronchus?

1. Relapsing polychondritis
2. Tracheobronchopathia osteochondroplastica
3. Tracheobronchial amyloidosis
4. granulomatosis with polyangiitis (GPA)

answer

2026.1.23