A Case of the Week

Case 422

A ninety-five-year-old female was transported by ambulance for hypoxemia and hypotension. He had slight fever during these three days. She experienced hypertension, cognition disorder, chronic cardiac failure and Parkinson disease. She took CT for further investigation.

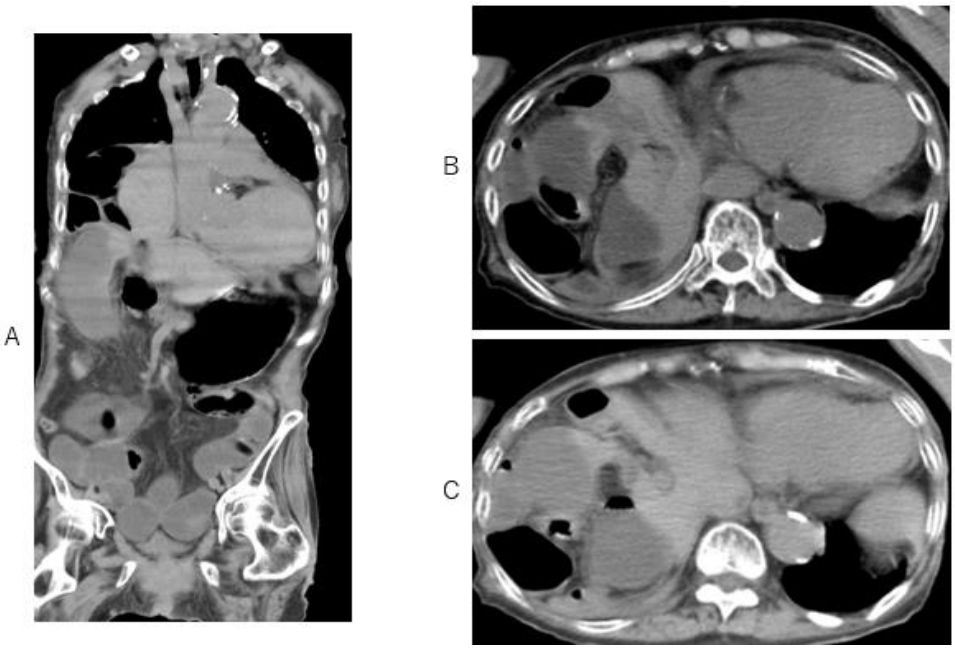

Fig.1 Swollen gall bladder with wedge-like or beak configuration at its neck corresponded to cystic duct is depicted on coronal and axial CT (A, B). Note that marked swollen small intestine of its diameter of 3cm or greater is depicted on coronal CT (A) and beak (V) sign (B, C) at gall bladder neck, corresponded to cystic duct torsion.

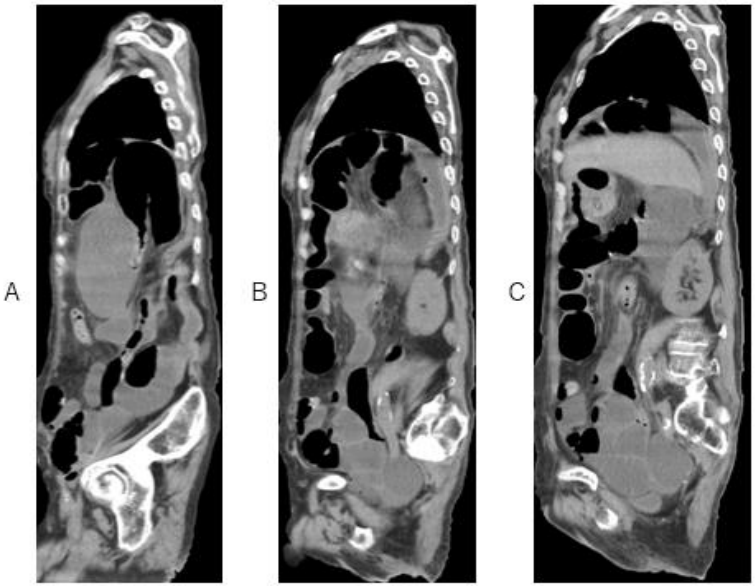

Fig. 2 Swollen gall bladder(A) with its neck corresponded to cystic duct like swirl configuration (B, C) is depicted on sagittal CT.

What is possible imaging diagnosis?

1. **Obturator hernia**
2. **Infectious enteritis**
3. **Gall bladder volvulus**
4. **Adeno-myxomatosis**

answer

2026.2.6