A Case of the Week

Case 424

A fifty-three-year-old male presented with a reference letter from a local clinic physician. It said that liver SOL whose sizes are around 20mm in diameter was found on ultrasound screening. He had diabetes mellitus. Laboratory test revealed blood sugar 158mg/mL, A1C 7.9, no elevation of tumor markers of CEA, CA19-9 and AFP. He took EOBMRI for further examination (Figs. 1, 2).

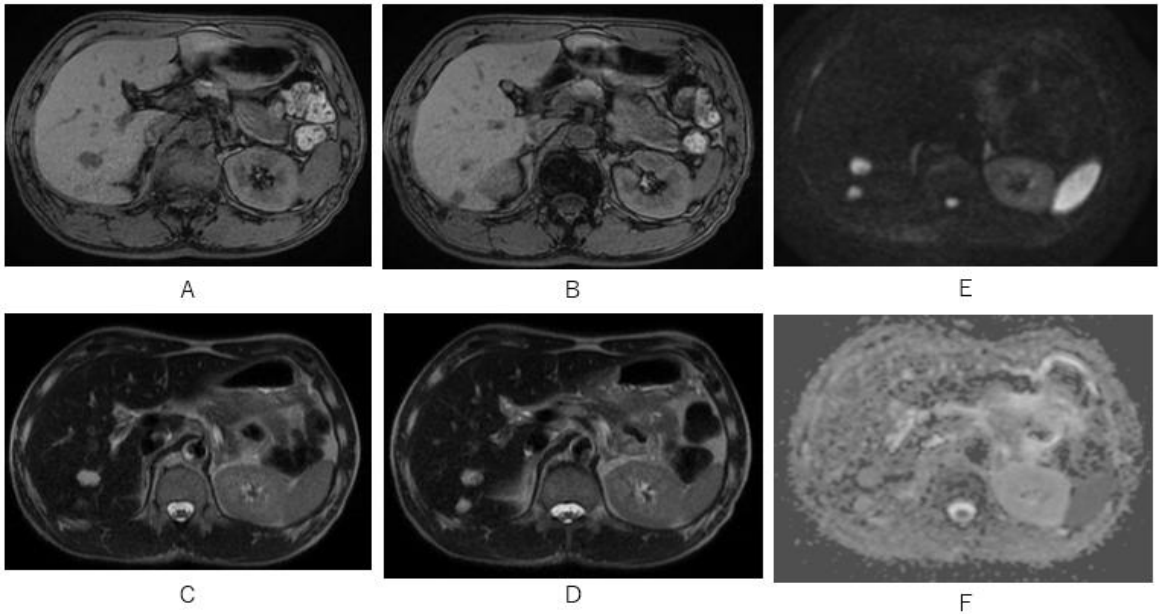

Fig.1 Pleural lesions in liver S6 are depicted with low signal intensity on T1WI (A, B), high signal intensity on T2WI (C, D), high signal intensity on Diffusion WI (E) and not lowering on ADC map (F).

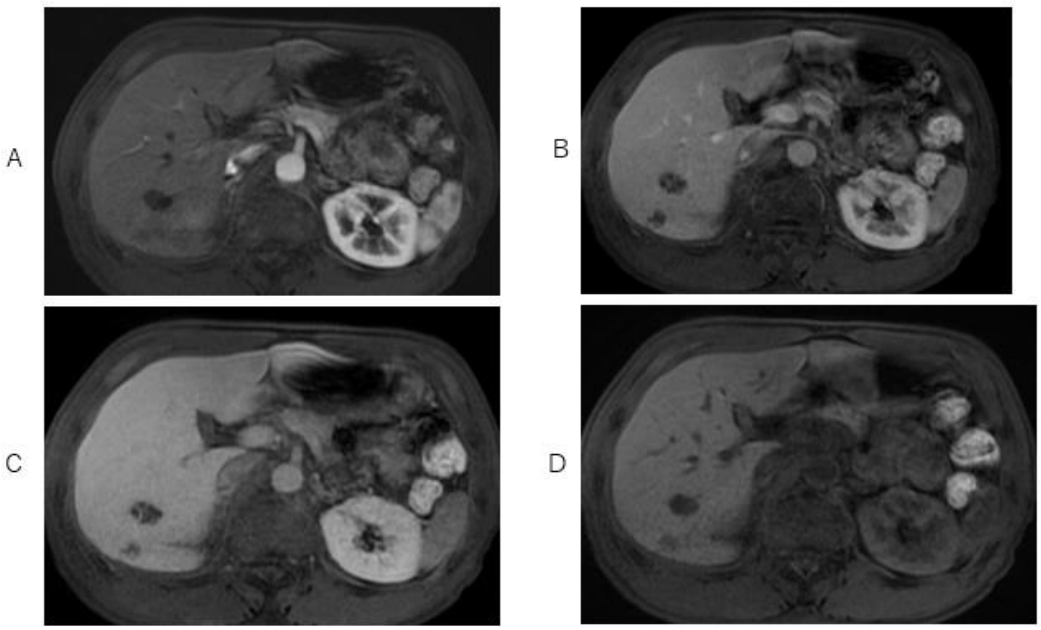

Fig.2 Hypo-vascular cystic lesions in liver S6 are depicted on arterial phase (A) of EOBMRI, septum like component in cystic lesions are depicted on portal and capillary phases of EOBMRI (C, D), and cystic lesions on hepatocellular phase (D).

What is probable imaging diagnosis?

1. **Mucinous cystadenoma**
2. **Multi-cystic biliary hamartoma**
3. **Caroli's disease**
4. **Intraductal papillary neoplasm of the biliary tracts**

answer

2026.2.20